

Cellulitis

S.S. Hamzavi MD

Subspecialty in pediatric infectious diseases

Shiraz University of Medical Sciences

Cellulitis

- The diagnosis of cellulitis : The subcutaneous tissues and dermis are involved
- Microbiology : **coagulase – positive staphylococci , GAS** , group B streptococcus (neonate) , *S. pneumoniae* , *H. Influenza* type b .
- In patients who are immunocompromised or have diabetes mellitus, other bacterial or fungal agents may be involved, notably *Pseudomonas aeruginosa* , *Enterobacteriaceae*; *Legionella* spp.; the *Mucorales*

cellulitis

- A break in the skin from previous **trauma, surgery**, or an underlying skin lesion predisposes to cellulitis.
- Cellulitis is also more common in individuals with lymphatic stasis, **diabetes mellitus, or immunosuppression**

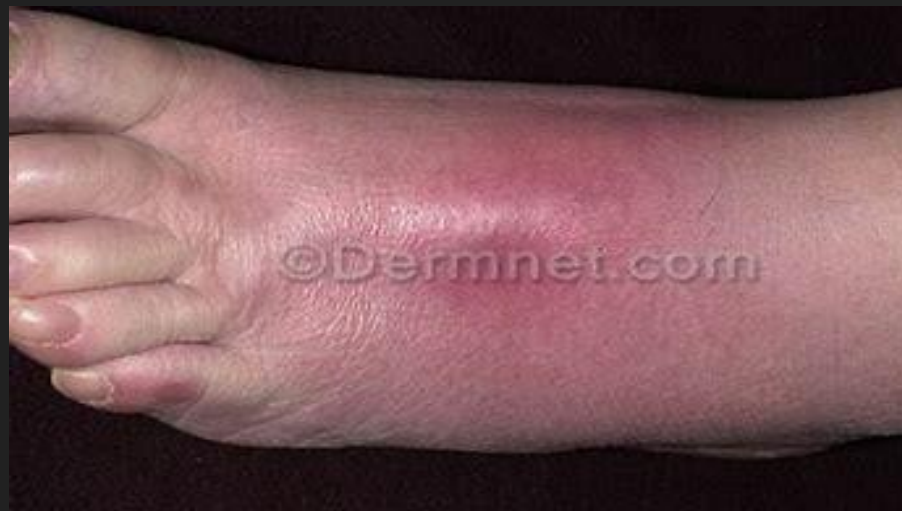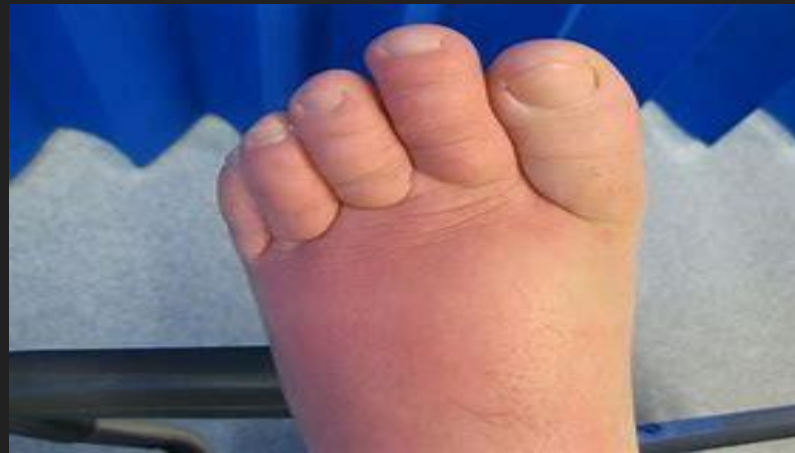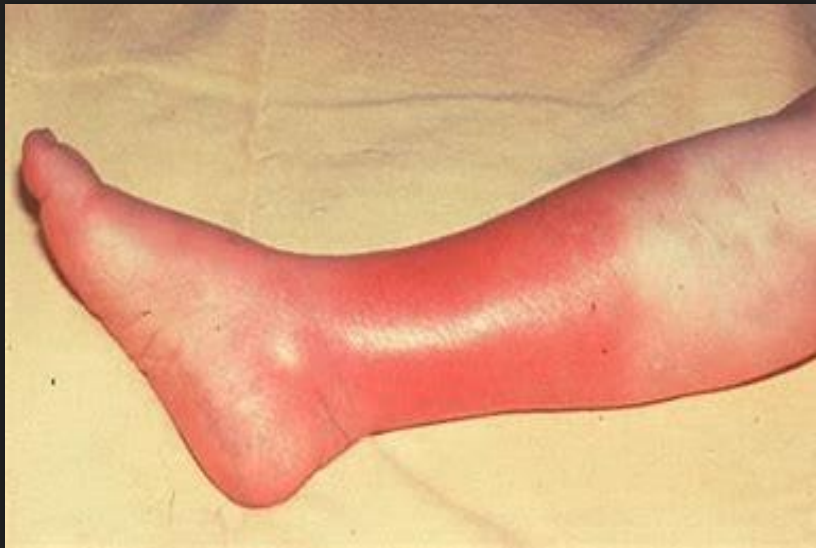Clinical manifestation

- Cellulitis manifest as areas of skin erythema, edema, and warmth
- The leading edge of the involved site may be notable , but it is not raised
- Fever , adenopathy
- Cellulitis is nearly always unilateral
- The lower extremities are the most common site of involvement

Skin abscess

- A skin abscess is a collection of pus within the dermis or subcutaneous space
- The most common cause of skin abscess is *S. aureus* (either methicillin-susceptible or methicillin-resistant *S. aureus* [MRSA
- Isolation of **multiple organisms** (including *S. aureus* together with *S. pyogenes* and gram-negative bacilli with anaerobes) is more common in patients with skin abscess involving the **perioral, perirectal, or vulvovaginal areas**

cellulitis



complications

- bacteremia, endocarditis
- septic arthritis or osteomyelitis
- metastatic infection, sepsis, and toxic shock syndrome .

Diagnosis

- The diagnosis of cellulitis, and skin abscess is usually based upon **clinical manifestations**
- Laboratory testing **is not required** for patients with uncomplicated infection in the absence of comorbidities or complications

culture

- Blood cultures should be considered if the patient is younger than 1 yr of age, if signs of systemic toxicity are present, if an adequate examination cannot be carried out, or if an immunocompromising condition (malignancy, neutropenia) is present
- Aspirates from the site of inflammation, skin biopsy, and blood cultures allow identification of the causal organism in approximately 25% of cases of cellulitis

Radiographic evaluation

- Radiographic evaluation may be warranted in patients with underlying immunosuppression, diabetes, venous insufficiency, or lymphedema and in patients with persistent systemic symptoms.
- to determine whether a **skin abscess** is present (**via ultrasonography**)
- for distinguishing **cellulitis from osteomyelitis** (**via magnetic resonance imaging**)

Admission

- Systemic signs, including fever ($>38^{\circ}\text{C}$ [100.4°F]), tachycardia, hypotension, or systemic inflammatory response syndrome
- Rapid progression of erythema
- Limb-threatening infection (necrotizing soft tissue infection, pyomyositis)
- Children with underlying medical problems that may be associated with poor response or complications (malignancy, primary immune deficiency, diabetes mellitus)
- Children who are unable to tolerate oral medications
- Children with SSTI close to an implanted device
- < 2 mo

Treatment

- Mild cellulitis in a normal child : oral antibiotic (cephalexin / clindamycin)
- **Parenteral antibiotic** : immunocompromised children / neonate / severe infection (high fever & toxicity).
- Simple cellulitis with a clear –cut area preceding trauma : **clindamycin**
- In infant with buccal or periorbital or in infant with soft tissue involvement but without a clear –cut focus of infection: **ceftriaxone +clindamycin**
- In toxic patient : **vancomycin**
- In immunosuppressed patient : **broad –spectrum therapy (gr neg + gr pos)**

Necrotizing fasciitis

- Necrotizing fasciitis is an infection of the deep soft tissues that results in progressive destruction of the muscle fascia and overlying subcutaneous fat
- Polymicrobial necrotizing fasciitis : *S. aureus* , streptococcal species, *Klebsiella* species, *E. coli*, and anaerobic bacteria
- Monomicrobial (type II) necrotizing infection is usually caused by GAS in the most cases of **pediatric fasciitis** .

Risk factors

- Traumatic lesions involving the skin , including varicella , burns , eczema .
- In neonates , omphalitis , circumcision
- Congenital or acquired immunodeficiencies
- surgical procedures , minor puncture wounds, abrasions, or lacerations; blunt trauma.

Clinical manifestations

- ●Erythema (without sharp margins; 72 percent)
- ●Edema that extends beyond the visible erythema (75 percent)
- ●**Severe pain (out of proportion to exam findings** in some cases; 72 percent)
- ●Fever (60 percent)
- ●Crepitus (50 percent)
- ●Skin bullae, necrosis, or ecchymosis (38 percent)
- **compartment syndrome** may develop, manifesting as tight edema, pain on motion, and loss of distal sensation and pulses; this is a surgical emergency

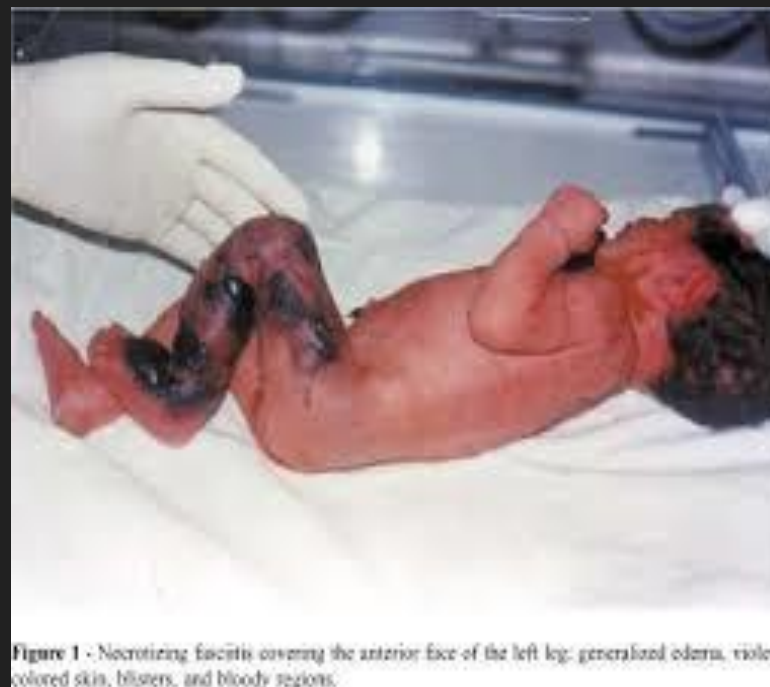
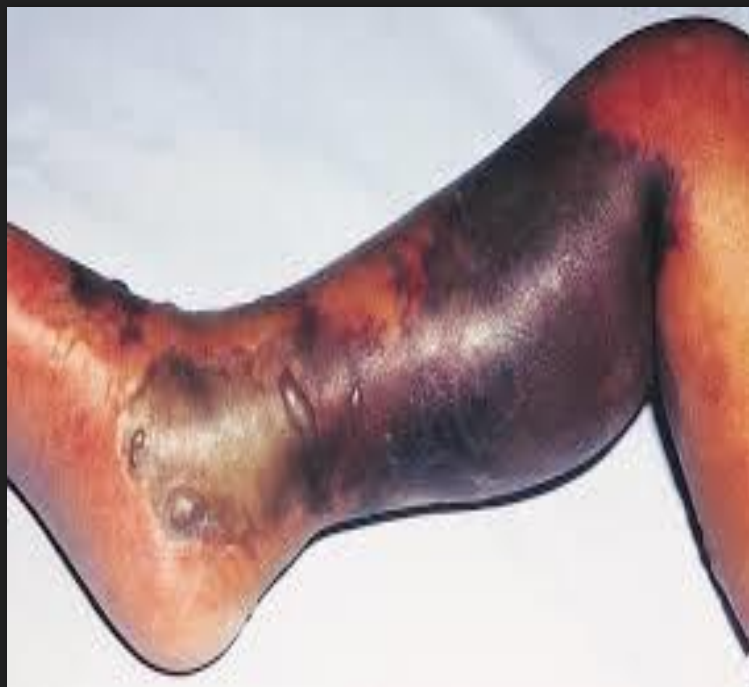
Figure 1 - Necrotizing fasciitis covering the anterior face of the left leg: generalized edema, violet-colored skin, blisters, and bloody regions.

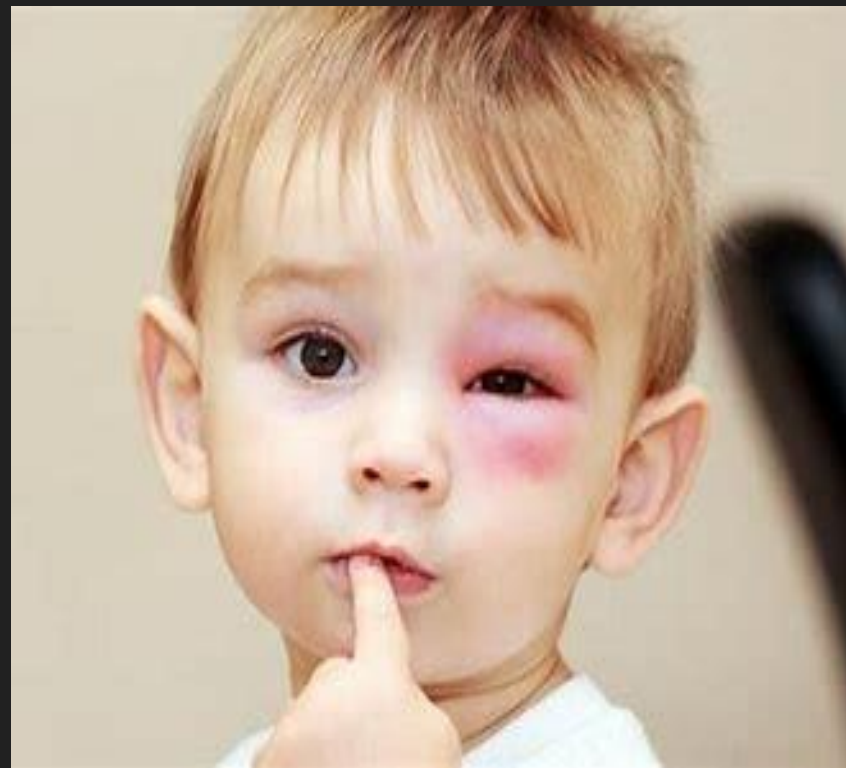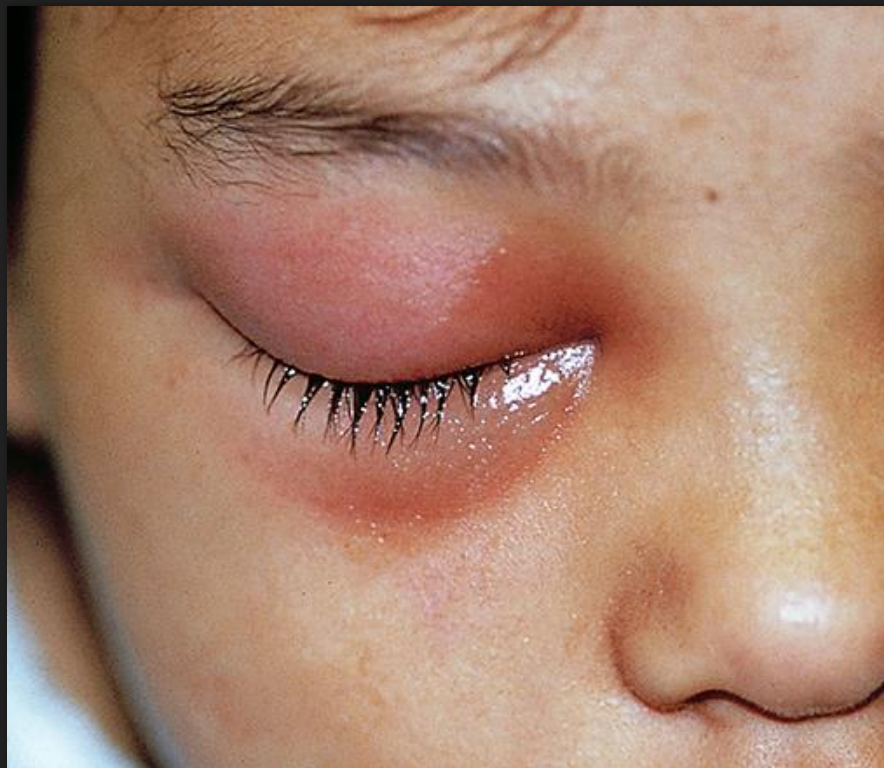Diagnosis

- Definitive diagnosis of necrotizing fasciitis is made by surgical exploration
- MRI (soft tissue edema infiltrating the fascial planes)

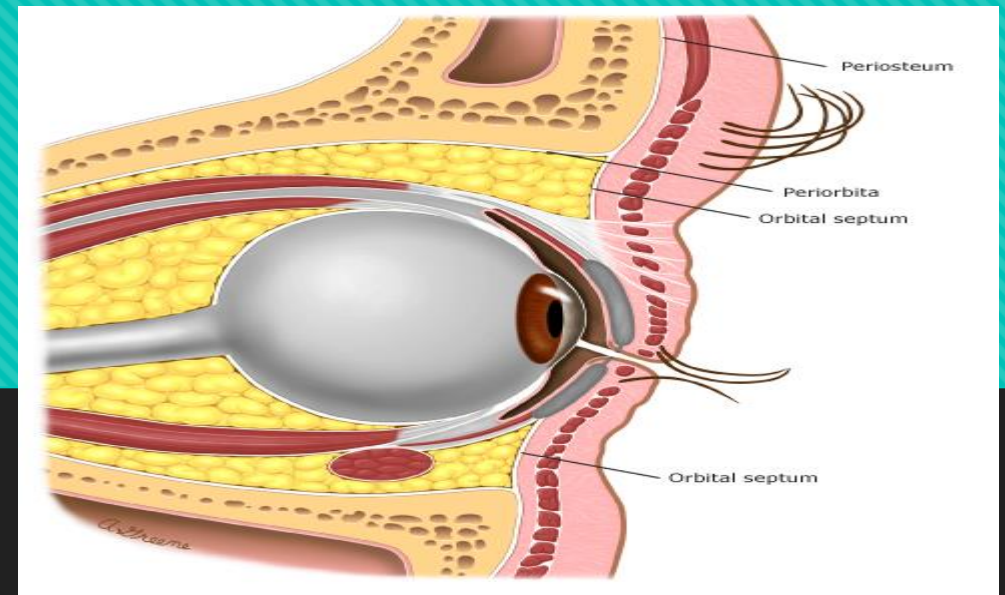
Management

- **Early and aggressive surgical exploration , broad-spectrum empiric antibiotic therapy and hemodynamic support**
- **ANTIBIOTIC** : Pencillin 150,000 U/kg/day + Vancomycin 40mg/kg + Clindamycin 40mg/kg
- In neutropenic patient :coverage of gr neg
- Hemodynamic instability may require aggressive supportive care with fluids and vasopressors
- Albumin replacement may be required in the setting of capillary leak syndrome
- Intravenous immune globulin (IVIG) for patients with NSTI in the setting of streptococcal TSS

Preseptal & orbital cellulitis



Preseptal cellulitis



- Preseptal (periorbital) cellulitis referring to infections of the soft tissues anterior to the orbital septum and orbital cellulitis referring to infections posterior to it
- orbital cellulitis is an infection involving the contents of the orbit (fat and ocular muscles)
- It is important to distinguish between preseptal and orbital cellulitis because the complications, treatments, and outcomes

Etiology

Orbital cellulitis

bacterial rhinosinusitis

Infection of the teeth , middle ear , or face.

Orbital trauma with fracture or foreign body

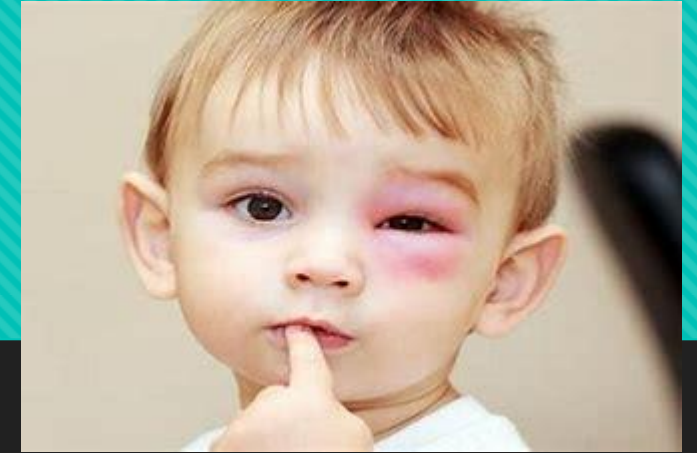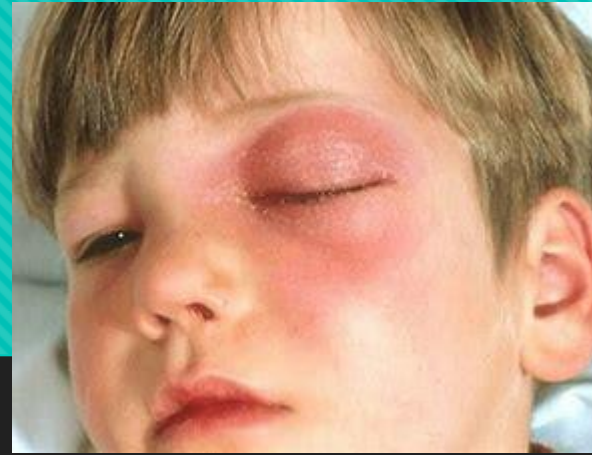Dacryocystitis

Preseptal cellulitis

trauma

Spread of infection from skin ,
upper respiratory system .

Clinical manifestations



- **preseptal cellulitis** : unilateral ocular pain, eyelid swelling, and erythema
- history of recent sinusitis, insect bite, or local face and/or eyelid trauma is supportive of the diagnosis
- **Orbital cellulitis**: include ophthalmoplegia with diplopia, pain with eye movement, altered visual , and proptosis
- **CT imaging** is also indicated in patients with presumed preseptal cellulitis who exhibit marked eyelid swelling, fever, and leukocytosis, or whose infection fails to show improvement after 24 to 48 hours of appropriate antibiotics.

Hospital admission

- Preseptal : children younger than 1 year of age
 - signs of systemic toxicity
 - inadequate H . Influenzae immunization

orbital cellulitis : all patients should be admitted .

Microbiology & Treatment

○ Preseptal :

1. post traumatic : s. aureus , s.pyogenes
2. nontraumatic : s.pneumoniae ,H.influenza type b

Intravenous : **clindamycin plus cefotaxime (or ceftriaxone)**

Orbital cellulitis

- group A streptococcus, streptococcus species (especially *Streptococcus anginosus* also known as the *Streptococcus milleri* group),
- and anaerobes (e.g., *Bacteroides* spp., *Prevotella* spp.).
- *S. aureus*
- *Streptococcus pneumoniae* , and less commonly *Haemophilus* species

Orbital cellulitis management

- Hospitalization
- CT imaging of the orbit, paranasal sinuses
- Lumbar puncture should be considered only in those with a meningitis presentation,
- Parenteral antibiotics should be initiated immediately
- Patients should be examined frequently (every 6 hr until improvement) for signs of visual deterioration or pupillary abnormalities
- **Antibiotic : clindamycin plus ceftriaxone**
- **vancomycin plus cefotaxime (or ceftriaxone) plus metronidazole** where there is suspicion for intracranial extensio

THANK YOU